

Aesthetic Management of Dental Fluorosis with Ceramic Veneers: A Case Report

D. Ouada*, A.Adli**, R.Dakhli**, N.Daouahi**, Z. Riahi*,
Z.Nouira***, B.Harzallah****, M.Cherif*****

* DDS, ** Associate Professor, *** Professor

**** Director of the Research Laboratory, Faculty of Dental Medicine, Tunisia

***** Head of the Department of Fixed Prosthodontics, Dentistry Clinic of Monastir, Tunisia.

* Corresponding Author: Amani Adli

ABSTRACT: Fluorosis has been reported way back in 1909(1). It is known as a hypo mineralization of the enamel that is characterized by greater porosity of the surface of healthy enamel due to excess fluoride consumption during the odontogenesis period leading to cosmetic concerns particularly when affecting the anterior teeth. This anesthetic aspect is characterized by dental discoloration, changes in the morphology caused by merging pits and marked attrition. (13) The treatment options for fluorosis are varied depending upon the fluorosis index firstly described by Dean and al in 1942. The purpose of this article is to report a case where the anesthetic aspect of dental fluorosis in a Tunisian female was managed using ceramic veneers.

KEYWORDS:- Dental Fluorosis, Ceramic Veneers, Smile analysis, Mockup, Bonding

I. INTRODUCTION:

Dental fluorosis, called “Colorado brown stains” by McKay in 1909 (10), is endemic in different parts of the world including Tunisia where 25% of children are affected (3). The global prevalence of dental fluorosis has been reported to be around 32% (7). Fluoridated water is, directly or indirectly, responsible for 40% of dental fluorosis. The other 60% are attributed to other sources of fluoride: the swallowing of excessive fluoride by young children with developing teeth, excessive tea drinking (9). This dental problem has been described by Dean and al in 1941 and 1942 (8).

Its major effects are unpleasant smile due to tooth discoloration, changes in its morphology and teeth worn. It also affects not only the socioeconomic status of our patients but also their self perception. (13)

Different treatment procedure options could be used to resolve this problem such as bleaching, micro abrasion, composite restorations which are prone to discoloration, ceramic veneers and conventional prosthetic procedures. (11)

Therefore, the aim of this article is to illustrate practically, step by step, a case of dental fluorosis management with ceramic veneers.

II. CASE REPORT:

A 32-year-old-female-patient presented to our department with a chief complaint “unpleasant aesthetics due to teeth discoloration and unsatisfactory teeth form”. A detailed dental and medical history revealed the presence of tooth discoloration since childhood and similar changes within family members.

The clinical examination showed a satisfactory oral hygiene. Enamel fluorosis was almost present on all dental surfaces: white opaque areas involving most of the tooth surface and brown stains were localized on the central maxillary incisors. A loss of outer surface of enamel in irregular areas was also observed on the anterior teeth (Fig1).

Class 1 occlusal relationship was present, 3mm overjet, 2mm overbite and periodontal health was within adequate requirement.

The radiography examination showed no caries or bone loss. Based on the history clinical findings and Dean’s index a diagnosis of moderate dental fluorosis was made. The decision was to perform porcelain veneers from tooth #13 to tooth #23.

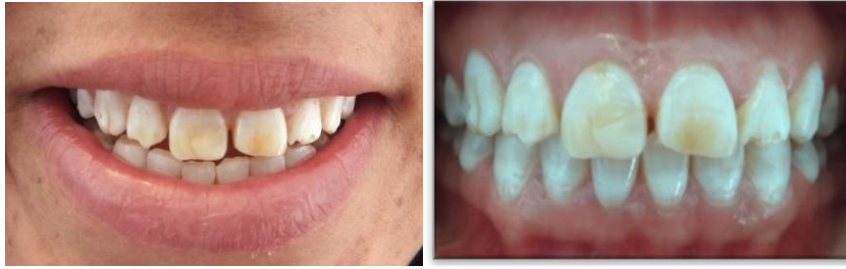

Figure1: Pretreatment intraoral and extraoral views

The first phase after oral prophylaxis included smile analysis and shade selection. Study cast and photographs were done and a detailed smile analysis was performed using “Digital smile design” (DSD) (fig2). Diagnosis wax up was done and showed to the patient (Fig3). The mock-up has helped her to understand what was offered to her, and she confronted it with what she was expecting (12). At the same time, we could control the function, occlusion, the posture of the lip, the smile line, and the phonetics (11). (fig4)

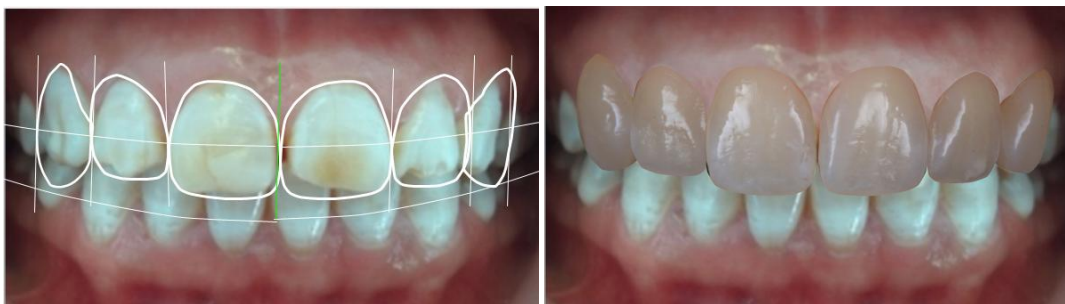


Figure2: digital smile design analysis

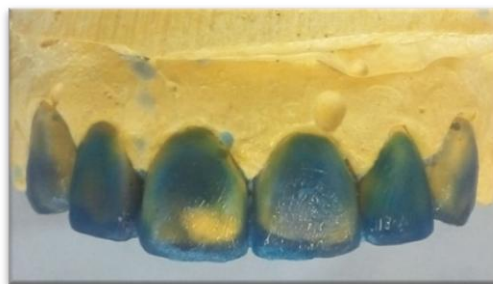

Figure3: Waxed diagnosis cast

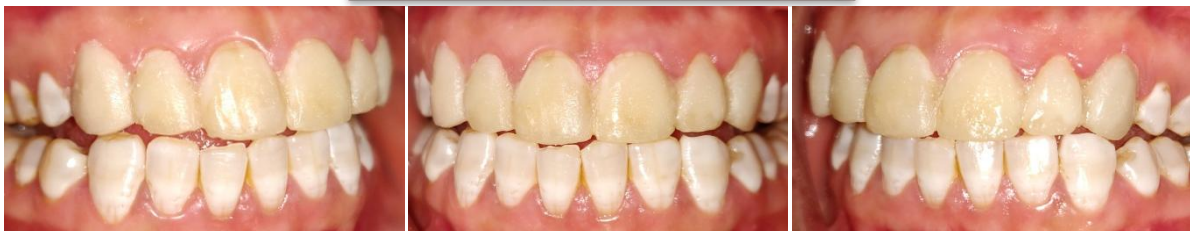
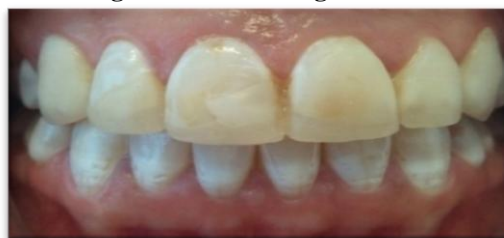
Figure4: intraoral views with the mock-up

Once the patient was satisfied, tooth preparation was initiated. After anesthetizing the planned teeth depth grooves were placed on the labial surface using depth burs over the mock up to achieve a minimal invasion of the teeth. The guidance grooves were done at 0.3 to 0.5 mm depth. The mock-up remnants were then removed and we continued the preparation which was oriented by the deepness of the grooves using a

chamfer diamond point (12). The preparation was extended on the intrasulphral proximal surfaces in order to close the diastema and 1.5 mm incisal reduction was made (Fig5).It also involved the elimination of an old resin restoration on the buccal surface of the tooth#11.

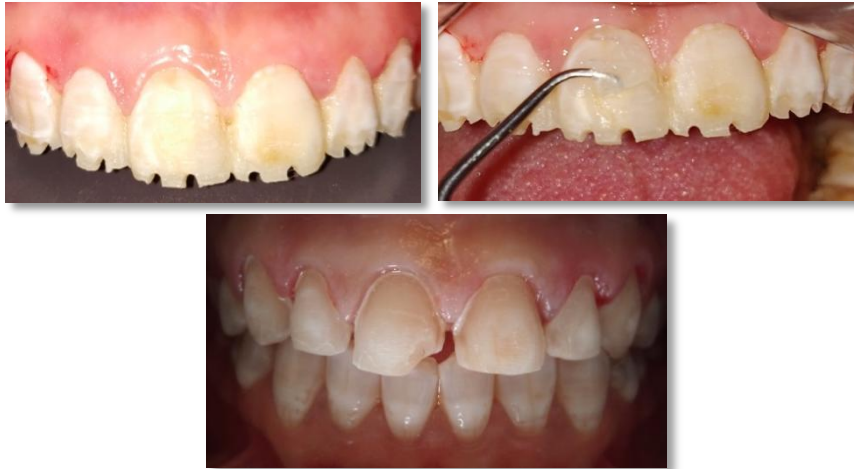

Figure5: tooth preparations

After teeth preparation was completed, gingival retraction was done using a gingival cord (C-00 Elsocord, Elsodent®), then the master impression was made using polyvinyl siloxane material (Elite HD+, Zhermack®). Provisional veneers were corresponding to the wax up previously done (Fig6). They were fixed to the teeth using undercuts.

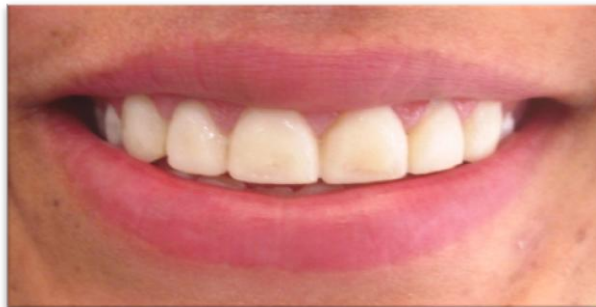

Figure 6: The patient's smile with provisional restorations

The master impression with the waxed diagnosis cast (communicated with photography), were sent to the dental laboratory and transformed into working casts.

The master cast was then scanned in laboratory (the physical impressions are poured with gypsum products including teeth). The design was performed through a copy scan of the mock up. Digital fabrication could then be processed by milling a lithium disilicate reinforced glass ceramic bloc (IPS e.max CAD) (Fig7).

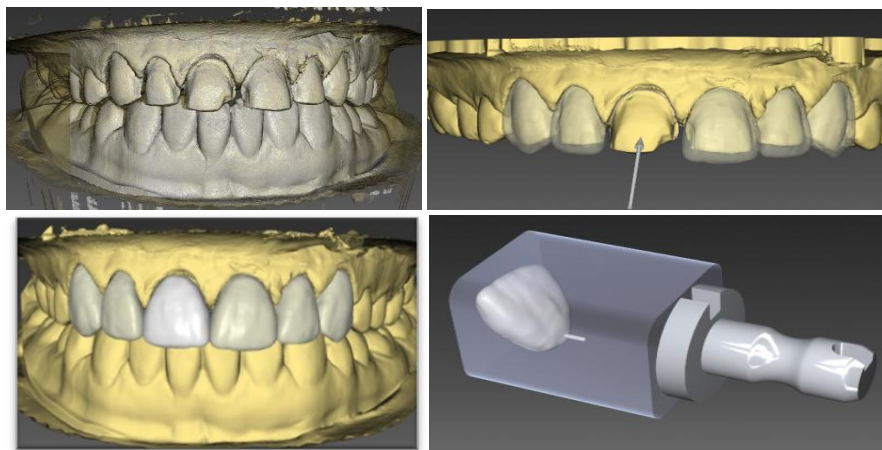


Figure 7: Veneers conception using Sirona Inlab

In the next session, the porcelain veneers were tried and checked firstly on the master cast. After tooth surfaces were cleaned up, the correct fit of the veneers was verified individually and collectively using the try-in paste: the adaptation and margin were critically evaluated. No rectification was necessary because of the perfect fit of the veneers. Once the fit and shade results were satisfactory for the clinician and the patient, final adhesive seating could be performed completely predictably. The cores were cleaned again with water spray and then the veneers were luted.

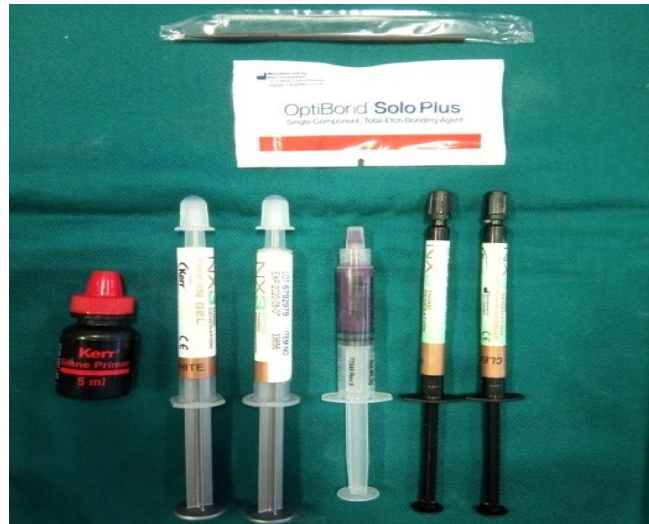

Figure 8: Bonding material (NX3 Nexus™, Kerr®)

The inner veneer surface was then etched using hydrofluoric acid for 20 seconds followed by silane application during 60 seconds and air drying.

Gingival protection was then initiated using a gingival retraction cord and a light curing dam. Each tooth surface was etched with 37% orthophosphoric acid for 15 seconds then rinsed and gently dried (Fig9).

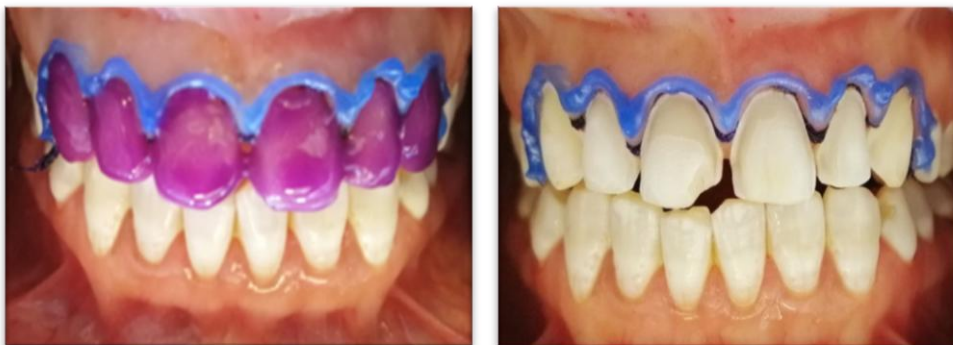

Figure 9: Tooth surface etching using 37 phosphoric acid

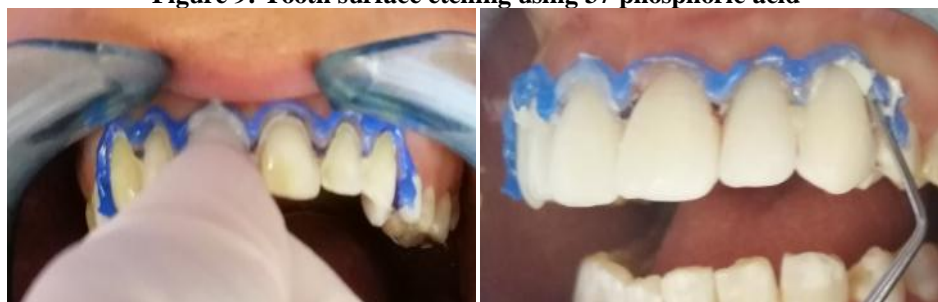

Figure 10: veneers luting and excess removal

The bonding agent was then scrubbed on each tooth surface and air spread in order to obtain a thin layer and to guarantee a right positioning of the ceramic veneers. The bonding agent was then light cured for 20 seconds. A thin layer of light curing resin luting cement (NX3 Nexus™, Kerr®) was applied on the inner surface of each veneer separately and was carefully placed with the thumb and forefinger, from incisal to cervical starting with the two central incisors, then the two lateral incisors and finally the canines.

Once the restoration surely seated, initial light curing was performed during 5 seconds followed by excess cement removal (Fig10). The light polymerization was completed on the palatal, labial and incisal sides and the margins were finished. The centric and eccentric occlusions were finally verified.

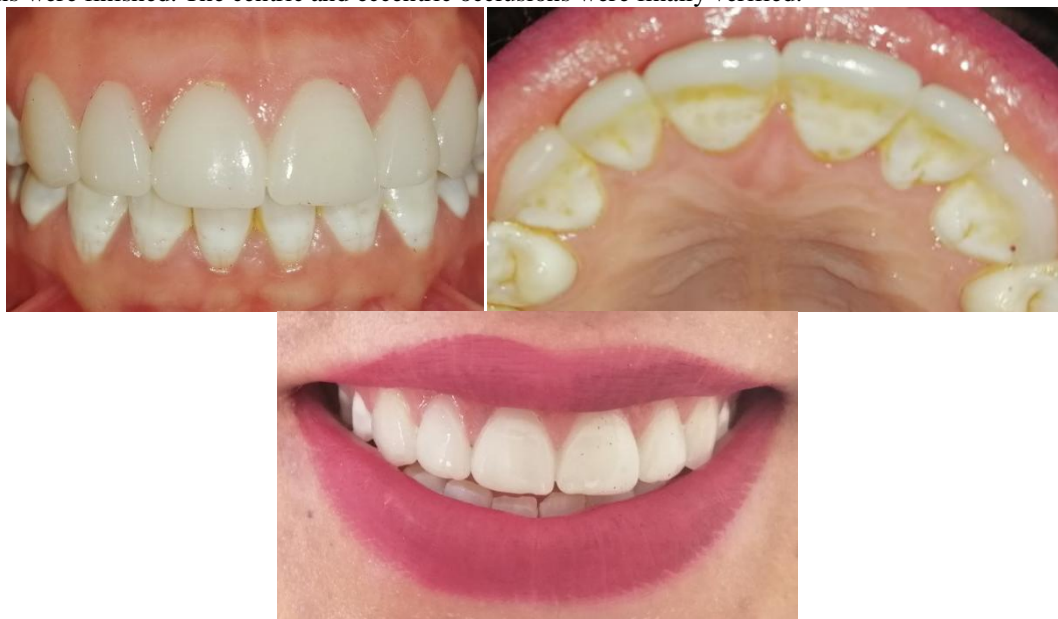

Figure 11: Post treatment views

III. DISCUSSION:

Dental fluorosis is a developmental disturbance of enamel caused by overconsumption of fluoride during critical ages which is estimated between 20 and 30 months age for permanent teeth (2). This excessive amount of fluoride disturbs enamel mineralization, inhibits enamel apatite crystal growth, and interferes with the degradation of enamel matrix proteins. As a result of the enamel structure defect, a whitish-brown enamel aspect is described depending on the severity of the dental fluorosis.

In Tunisia, dental fluorosis is a major problem particularly in the endemic areas where phosphate fields are concentrated in fact, 25% of the Tunisian population is at a high risk of dental fluorosis according to researchers (3).

Therefore different approaches have been mentioned in order to manage the aesthetic aspect of dental fluorosis depending on its severity:

Bleaching which is more successful for fluorosis in young patients presenting with opaque to orange colour stain rather than older patients with darker type of brown stains

Micro-abrasion for mild to moderate cases is considered as a faster procedure in achieving the desired result compared to other treatment options. However, the main disadvantage is that these procedures employ high speed rotary instrument which can lead to excessive removal of tooth structure if operator does not have the desired skill level (13)

Both the bleaching technique and abrasion procedures could be employed only for mild to moderate grade fluorosis employed. The main advantage is minimal chair time needed when compared to indirect ceramic veneers. Whereas it offers a bad color stability and long term wear resistance.

Veneering is indicated for managing moderate grade fluorosis whereas crowning is employed for severe cases where a corroded appearance of the tooth is mentioned and loss of inter-occlusal space (4).

Ceramic veneers have firstly been introduced in 1938 and ever since their popularity has increased as they afford both biocompatibility and aesthetics. Their main indications include stained or darkened teeth, hypocalcifications, diastema, chipped teeth, slightly rotated teeth, discrepancies in size and shape of teeth, worn acrylic veneers, foreshortened teeth, slight deviation of midlines, stained restorations and lingually positioned teeth (5).

In this case, ceramic veneers were indicated in order to correct the shape of teeth, close diastema and manage dental fluorosis. The main problem encountered in dental fluorosis remains enamel bonding. As a solution grinding the enamel surface with a diamond instrument or extending the normal etching time with phosphoric acid 37% were described as they improve enamel adhesion. (6)

A double etching protocol was previously described in order to improve bonding to fluorosis enamel otherwise according to a comparative study of the simple and the double etching protocol no significant differences were observed in adhesion quality between both protocols (14).

In fact, the bond strength of fluorosis tooth increases with the increasing concentration of phosphoric acid and also depends on the degree of fluorosis but an excessively high acid concentration can conversely lead to an apparent decline in bond strength. (15)

A 6 month follow up after treatment demonstrated a confident and satisfied patient. All restorations were fixed in place, aesthetics were very good, margins sound, and with no staining nor discoloration.

IV. CONCLUSION:

Prevention remains the best way to avoid the anesthetic aspect of dental fluorosis by controlling the fluoride intake. However when this is already installed and causing esthetic problems to the patient, different treatment techniques are described depending on the severity of the situation (2).

In some cases, these different treatment options could be combined.

Minimally invasive solutions should be indicated first in order to preserve the dental tissue, provided they meet aesthetic expectations.

REFERENCES:

- [1]. Maatouk F. School oral health survey in Kairouan, Tunisia. *EMHJ - Eastern Mediterranean Health Journal*.1998;4(1):137-141.
- [2]. Alvarez JA, Rezende KM, Salazar Marocho SM, Alves F, Celiberti P, Ciamponi AL. Dental fluorosis: Exposure, prevention and management. *Med Oral Patol Oral Cir Bucal*. 2009 Feb 1;14(2):E103-7.
- [3]. Guissouma W, Hakami O, Al-Rajab A J. Risk assessment of Fluoride exposure in drinking water of Tunisia. *Chemosphere*. 2017 Jun ;177 : 102-108
- [4]. Douki Zbidi N, Zouiten S, Hajjami H, Baccouche C. Le traitement de la fluorose dentaire. *Odonto-Stomatologie Tropicale*. 2003 ;104 : 29-32.
- [5]. Jhahharia K, Shah HH, Paliwal A, Parikh V, Patel S. Aesthetic management of fluoresced teeth with ceramic veneers and direct composite bonding - An overview and a case presentation. *J Clin Diagn Res*. 2015 Jun; 9(6):ZD28-30. 6/ Swift Jr. Bonding to fluorosed enamel. *J Esthet Restor Dent*. 2009; 21(3):147-8.
- [6]. Du Toit J, Patel N, Montalli V, Jain S. Aesthetic treatment of severely fluorosed teeth with prefabricated composite veneers: a case report. *International dentistry- African edition* .2012;2(6):44 - 50
- [7]. Goodarzi F, Mahvi AH, Hosseini M, Nedjat S, Nabizadeh Nodehi R, Kharazifard MJ, Parvizishad M, Cheraghi Z. The prevalence of dental fluorosis and exposure to fluoride in drinking water: A systematic review. *J Dent Res Dent Clin Dent Prospects*. 2016;10(3):127-35.
- [8]. Fernandes CM, Tabchoury CM, Cury JA. Fluoride concentration in infant foods and risk of dental fluorosis. *J Dent Res*. 2001; 80:224.
- [9]. National institute of dental and craniofacial research. The Story of Fluoridation. July 2018. <https://www.nidcr.nih.gov/health-info/fluoride/the-story-of-fluoridation> consulté le 12/06/2019
- [10]. I Anand Scherwood.
- [11]. Fluorosis varied treatment options.
- [12]. *J Conserv Dent*. 2010 Jan-Mar; 13(1): 47–53. 12/ Galip Gürel. Minimally invasive veneers *International dentistry – African edition*. 2016; 6(6):40-48
- [13]. N M Frechero, M Nevarez-Rascón, A Nevarez-Rascón, R González-González, M E Irigoyen-Camacho, L Sánchez-Pérez, S López-Verdin, R Bologna-Molina.
- [14]. Impact of dental fluorosis, socioeconomic status and self-perception in adolescents exposed to a High Level of Fluoride in Water. *Int J Environ Res Public Health*. 2017 Jan; 14(1): 73. 14/ C Belkhir, A Arous, M S Belkhir.
- [15]. Adhesion to mild fluorosed enamel: A comparative study of two etching protocols. *Dental News* June 2014
- [16]. Gu M, Lv L, He X, Li W, Guo L. Effect of phosphoric acid concentration used for etching on the microtensile bond strength to fluorotic teeth. *Medicine (Baltimore)*. 2018 Aug;97(35).

***Corresponding Author: Amani Adli**

**** Associate Professor, Fixed Prosthodontic Monastic, Faculty of Dental Medicine, Tunisia**