

Evaluation of Hearing Impairment in Patients with Oral Submucous Fibrosis

Dr. Sriram G¹, Dr. Harish Vel V², Dr. Swetha Lakshmi M³

¹Assistant professor Department of Otorhinolaryngology, Vinayaka Mission's Medical College & Hospital, Karaikal, Puducherry 609609

²Post graduate, Department of Otorhinolaryngology, Vinayaka Mission's Medical College & Hospital, Karaikal, Puducherry 609609

³Post graduate, Department of Otorhinolaryngology, Vinayaka Mission's Medical College & Hospital, Karaikal, Puducherry 609609

*Corresponding Author: Dr. Harish Vel V²

ABSTRACT:-

Objective: To evaluate, hearing impairment in patients with Oral SubMucous Fibrosis (OSMF)
Study Design: Prospective study with 40 OSMF patients subjected to Audiological examination with Pure Tone Audiometry (PTA).

Results: The audiometric analysis showed significant differences in hearing abilities in various grades of OSMF. Further, there was a significant increase in severity of hearing dysfunction with increase in severity of disease.

Conclusions: From the present study it is evident that the subjective function of Eustachian tube may be affected by disease process of OSMF which may results in middle ear disfunction ,leading to hearing impairment.

KEYWORDS: Oral submucous fibrosis, OSMF, hearing loss, puretone audiometry, PTA

I. INTRODUCTION:

Oral submucous fibrosis (OSMF) is a chronic progressive and irreversible disease.,involving oral, oropharyngeal and esophageal mucous membrane[1], characterized by juxta-epithelial deposition of fibrous tissue ,which results in fibroelastic changes of lamina propria with epithelial atrophy causing trismus. It is similar to scleroderma but limited to oral tissues [2].

In 1953 the term "Oral submucous fibrosis" was first coined by SG Joshi. This is a premalignant condition[3],which is more common in males . It affects about 0.2–1.2% of Indian population. 4–13% of OSMF has malignant transformation worldwide and 7.6% in Indian population.[4-6]

In 1966 Pindborg and Sirsat [1]defined OSMF as "an insidious chronic disease affecting any part of the oral cavity including the pharynx.Most common cause is areca nut chewing. Other factors includes Capsaicin, Betel nut alkaloids, Alcohol, Smoking, hypersensitivity, autoimmunity, genetic predisposition and chronic iron and vitamin B-complex deficiency[7].

Histologically there will be fine fibrils of collagen, edema, hypertrophic fibroblast, dilated and congested blood vessels with infiltration of neutrophilic and eosinophilic granulocytes in early stages .In late stage there will be a down regulation of fibroblast, epithelial atrophy and appearance of hyalinization with an infiltration of inflammatory cells,which affects the underlying muscles and deeper tissues.[8]

Patient most commonly presents with burning sensation in oral cavity, and ulceration of oral mucosa. They may also have loss of pigmentation ,blanching and leathery texture of oral mucosa,with progressive reduction in mouth opening.The ventilatory function and patency of eustachian tube may be impaired if the muscles are involved in OSMF, this result in failure of eustachian tube to effectively regulate air pressure and middle ear drainage which may lead to conductive hearing loss.

The aim of the present study was to evaluate the hearing impairment in patients with OSMF.

II. MATERIAL AND METHODS:

The study was conducted at Dept of Oto Rhino Laryngology, Vinayaka mission medical college and hospital, Karaikal, Puducherry State, India, between November 2018 and December 2019 on 40 OSMF patients after taking ethical committee clearance of the institution.

INCLUSION CRITERIA

- Age between 18 -55 years
- Both male and female
- Patients diagnosed as having OSMF

EXCLUSION CRITERIA

- Age <18years >55 years
- Patient,with h/o Hearing loss prior to the onset of OSMF
- History of Ear Discharge
- Perforated Tympanic membrane
- Cholesteatoma
- Previous Ear surgery
- Other oral lesions

After obtaining written informed consent from the patients, history was elicited and through clinical examination was done. The diagnosis of OSMF was established. Study group was divided into four groups based on inter-incisal mouth opening Grading.

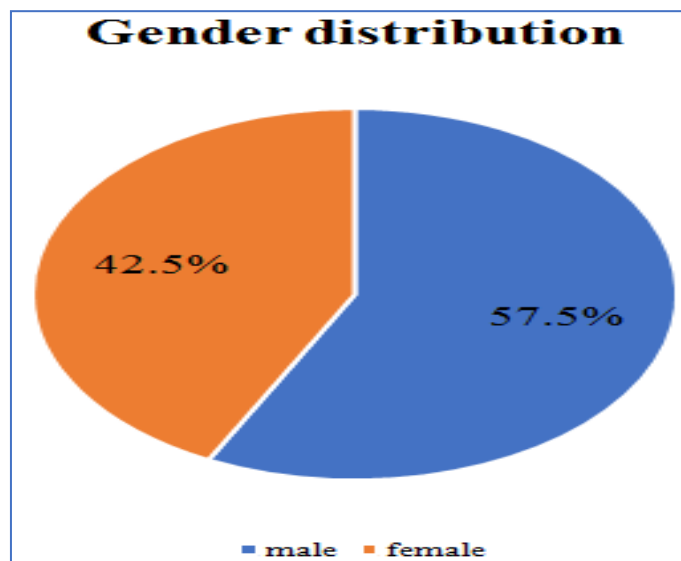
- Group A (inter-incisal distance \geq 35 mm),
- Group B (25-35 mm),
- Group C (15-25 mm) and
- Group D (2-15mm) .

Later all the groups were subjected for audiological evaluation by Pure tone audiometry [PTA].using. 250 – 8000 Hz of frequency. Average of 500, 1000 and 2000 Hz was calculated for assessing hearing threshold. Hearing impairment is graded based on air conduction threshold into several categories:

1. 10-15 dB - Normal hearing
2. 16-25 dB - Minimal hearing loss
3. 26-40 dB - Mild
4. 41-55 dB - Moderate
5. 56-70 dB - Moderate to severe
6. 71-90 dB - Severe
7. >90 dB - Profound deafness

III. RESULTS

Study was done in Dept of Oto Rhino Laryngology, Vinayaka mission medical college and hospital, Karaikal, Puducherry, India on 40 OSMF patients. Study included 23 males and 17females, aged between 18 and 55 years.

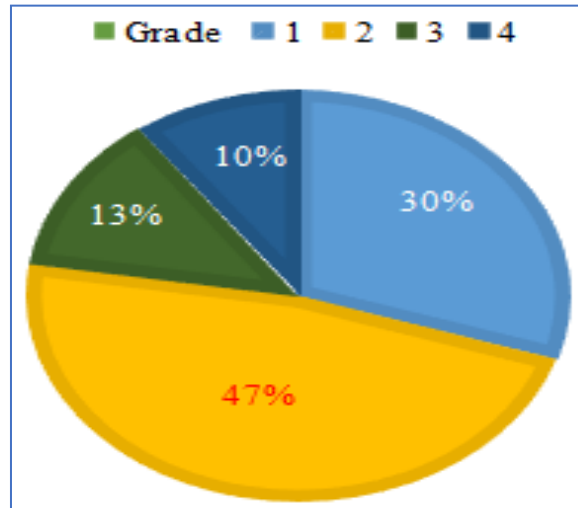


Graph: 1 Gender Distribution

Results were statistically evaluated using the Statistical Package for Social Service (SPSS) 16 software for Microsoft windows.

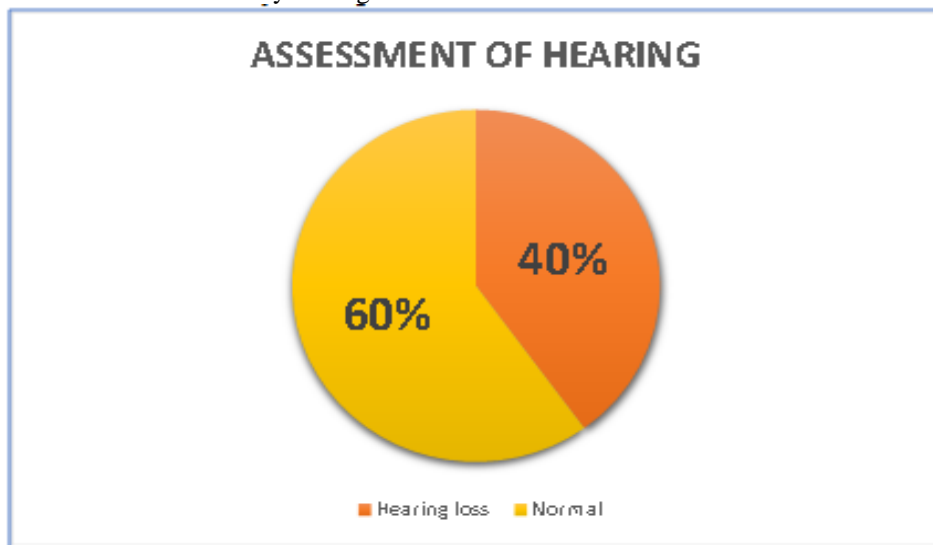Grade	Number of patients	Percentage of patients
1	12	30%
2	19	47.5%
3	5	12.5%
4	4	10%

Table 1: Grading Of Osmf Patients



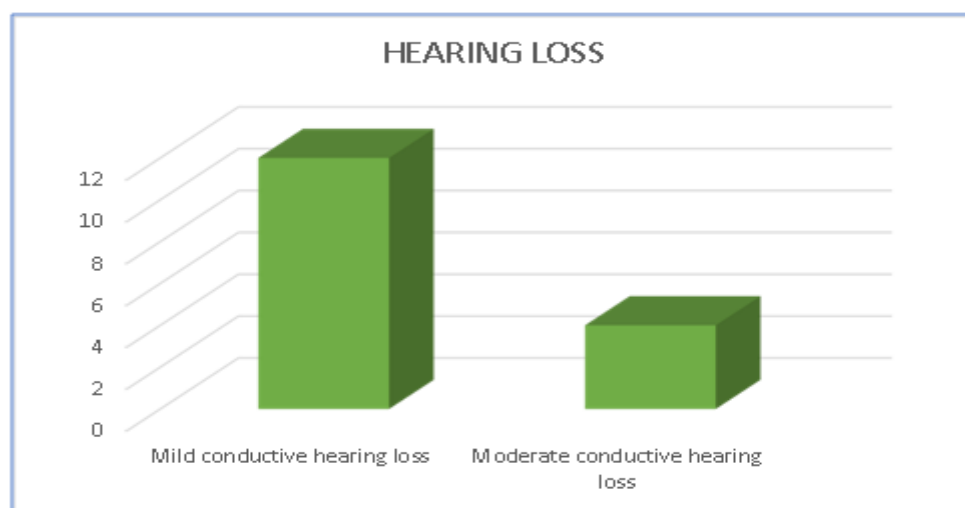
Graph: 2 Grade Distributions

In PTA out of 40 patients with oral submucous fibrosis 16 (40%) patients had hearing loss and 24 (60%) patients had normal audiometry findings.



Graph: 3 Assessment of Hearing

Among 16 patients 12 (75%) had mild conductive hearing loss, 4 (25%) had moderate conductive hearing loss.



Graph: 4 Type Of Hearing Loss

IV. DISCUSSION:

Oral submucous fibrosis (OSMF) is a precancerous condition which affects mainly the oral mucosa. Pathogenesis is by a) reduced phagocytosis of collagen by fibroblasts, b) up or down regulation of key enzymes such as lysyl oxidase, matrix metalloproteinases and tissue inhibitors of matrix metalloproteinases. This process may also be influenced by increased secretion of inflammatory cytokines, growth factors and decreased production of anti-fibrotic cytokines [7].

Infiltration of inflammatory cells in OSMF involves underlying muscles and deeper fibres. Oliver AJ et al. reported the presence of dense collagen bundles extended into the underlying striated muscles [9] and El Labban NG et al compared ultrastructural changes in the muscle fibers of normal individuals and OSMF patients. OSMF patients had severe degenerative changes in underlying submucosal muscle fibers.[10] Rajendran et al. found extensive fatty infiltration and hypercontraction of myofibers between muscle bundles in biopsy samples from OSMF patients[8].

Evaluation of the ultrastructural features of muscle tissue in the moderate and advanced stages of OSMF done by Sumathi et al. found changes in muscle fibers, including irregularity of the fiber surfaces, sarcolemmal folding, loss and alteration of myofilaments, reduplication of the basement membrane and hypercontraction of myofibrils.[11]

Eustachian tube is approximately 36 mm in length 3mm diameter which is directed downward, forward, and medially, connecting the naso pharynx to the middle ear cavity. Lateral one third is bony(12mm) and medial two thirds (24 mm) is cartilaginous. The muscles attached to the eustachian tube are tensor veli palatine, levator veli palatine, salpingopharyngeus, tensor tympani. The eustachian tube acts as a equalizer in maintaining middle ear pressure with that of atmospheric pressure by opening and closing The ventilatory function and patency of eustachian tube may be impaired if the muscles are involved in OSMF, this result in failure of eustachian tube to effectively regulate air pressure and middle ear drainage. If there is a impairment in this mechanism it will lead to changes in the middle ear pressure and drainage, which will result in pathological changes in the middle ear. This in turn can cause hearing impairment .[12,13]

OSMF leads to difficulty in speech and swallowing, pain in the throat and ears, and a relative loss of auditory acuity [14]. Many studies have shown progressive degeneration of the underlying musculature, causing impairment of ET function. Palatal involvement is seen in more than 50% of patients with fibrosis in the faucial pillars [15]. Involvement of palatal and paratubal muscles (levator veli palatini, tensor veli palatini, tensor tympani and salpingopharyngeus), which regulate the patency and function of the ET-pharyngeal orifice, results in impairment of eustachian tube function and patency [16], leading to hypoventilation and later effusion of in the middle ear, fibrosis and ossicular fixation, which leads to conductive hearing loss [15].

Gupta et al. reported degenerative changes in the palatal/paratubal muscles in the form of loss of cross-striations in 13.2% of cases, edematous muscle fibers in 9.4%, and atrophy in 9.4%. That study confirmed that extension of fibrosis into the nasopharynx, involving the pharyngeal orifice of the eustachian tube and changes in the muscles, affected the function of the eustachian tube.[17]

Esophageal fibrosis also causes loss of hearing in advanced cases due to blockage of eustachian tubes and difficulty swallowing.[18]

Shah et al reported that in 27 OSMF patients, hearing was normal in 67%, mild sensorineural hearing loss was found in 22%, and moderate mixed hearing loss in 11%. [19]

In the our study, pure tone audiometry was done in 40 OSMF patients out of which 16 (40%) patients had hearing loss and 24 (60%) patients had normal audiometry findings. Among 16 patients 12 (75%) had mild conductive hearing loss, 4 (25%) had moderate conductive hearing loss. Our results were in accordance with the study done by Gupta et al, where hearing was found to be normal in 79.2% of ears, mild to moderate conductive hearing loss was evident in 18.0%, and sensory neural hearing loss was evident in 2.8%.

V. CONCLUSION:

Thus, our study suggests that audiological impairment can be associated with OSMF, hence all OSMF patients should undergo Audiological evaluation, as a part of the routine clinical workup, so that OSMF can be treated at early stages of the disease, to avoid hearing impairment in the patients. However, a further study on OSMF in a larger sample size is required to further validate these findings.

REFERENCES:

- [1]. Pindborg JJ, Sirsat SM. Oral submucous fibrosis. *Oral Surg Oral Med Oral Path* 1966;22:764-79.
- [2]. Arakeri G, Brennan PA (2013) Oral submucous fibrosis: an overview of the aetiology, pathogenesis, classification, and principles of management. *Br J Oral Maxillofac Surg* 51, 587-593.
- [3]. Shevale VV, Kalra RD, Shevale VV, Shringarpure MD (2012) Management of oral sub-mucous fibrosis: a review. *Indian J Dent Sci* 4, 107-114.
- [4]. McGurk M, Craig GT. Oral submucous fibrosis: Two cases of malignant transformation in Asian immigrants to the United Kingdom. *Br J Oral Maxillofac Surg* 1984;22:56-64.
- [5]. Misra SP, Misra V, Dwivedi M, Gupta SC. Oesophageal subepithelial fibrosis: An extension of oral submucosal fibrosis. *Postgrad Med J* 1998;74:733-6
- [6]. Pundir S, Saxena S, Aggrawal P. Oral submucous fibrosis a disease with malignant potential - Report of two cases. *J Clin Exp Dent* 2010;2:e215-8.
- [7]. Tilakaratne WM, Klinikowski MF, Saku T, Peters TJ, Warnakulasuriya S. Oral submucous fibrosis: Review on aetiology and pathogenesis. *Oral Oncology*. 2006;42:561-8.
- [8]. Rajendran R. Oral submucous fibrosis. *J Oral Maxillofac Pathol*. 2003;7:1
- [9]. Oliver AJ, Radden BG. oral submucous fibrosis. Case report and review of literature. *Aust Dent J*. 1992;37:31-4
- [10]. El Labban NG, Caniff JP. Ultra structural finding of muscle degeneration in oral submucous fibrosis. *J Oral Pathol*. 1985;14:709-17
- [11]. Sumathi MK, Balaji N, Malathi N (2012) A prospective transmission electron microscopic study of muscle status in oral submucous fibrosis along with retrospective analysis of 80 cases of oral submucous fibrosis. *J Oral Maxillofac Pathol* 16, 318-324.
- [12]. Schames J, Schames M, King K, Ulansey S, Boyd J, et al. (2002) Trigeminal pharyngioplasty: Treatment of the forgotten accessory muscles of mastication which are associated with Orofacial Pain and Ear Symptomatology. *AJPM* 12: 102-112
- [13]. S.C.Gupta, Mangal Singh, Sanjay Khanna, Sachin Jain (2004) Oral submucosal fibrosis with its possible effect on eustachian tube functions: A Tympanometric study. *Indian Journal of Otolaryngology & Head & Neck Surgery* 56: 183-185.
- [14]. Chaudhary MS, Mohite DP, Gupta R, Patil S, Gosavi S, Gawande M et al. (2013) Evaluation of hearing efficiency in patients with oral submucous fibrosis. *Otolaryngology*, doi: 10.4172/2161-119X.1000143.
- [15]. Gupta SC, Khanna S, Singh M, Singh PA (2000) Histological changes to palatal and paratubal muscles in oral submucous fibrosis. *J Laryngol Otol* 114, 947-950.
- [16]. Misra SP, Misra V, Dwivedi M, Gupta SC (1998) Oesophageal subepithelial fibrosis: an extension of oral submucosal fibrosis. *Postgrad Med J* 74, 733-736.
- [17]. Gupta SC, Khanna S, Singh M, Singh PA (2000) Histological changes to palatal and paratubal muscles in oral submucous fibrosis. *J Laryngol Otol* 114, 947-950.
- [18]. Kerr AR, Warnakulasuriya S, Mighell AJ, Dietrich T, Nasser M, Rimal J et al. *Oral Diseases*. 2011;17(Suppl.1):42-57.
- [19]. Shah M, Katarkar A, Shah P, Alam N, Modh D (2011) Tympanometric study of eustachian tube /function in oral submucous fibrosis. *Indian J Otolaryngology* 17, 80-82.

***Corresponding Author: Dr. Harish Vel V²**

²Post graduate, Department of Otorhinolaryngology, Vinayaka Mission's Medical College & Hospital, Karaikal, Puducherry 609609